

# A Unique NIPT Discordance: FISH Comes to Rescue

Nivedita Rajakumar<sup>1</sup>, Sheetal Sharda<sup>1</sup>, Samarth Bhatt<sup>1</sup>, Parth Shah<sup>2,3</sup>, Shiva Murarka<sup>1,\*</sup>

<sup>1</sup>Department of Molecular Genetics, Neuberg Supratech Reference Laboratories, Ahmedabad, Gujarat, INDIA.

<sup>2</sup>Department of Pathology and Laboratory Medicine, Center for Genomics and Advanced Technologies, Dartmouth Hitchcock Medical Center, Lebanon, New Hampshire, UNITED STATES OF AMERICA.

<sup>3</sup>Department of Hematology and Oncology, Norris Cotton Cancer Center, Dartmouth Hitchcock Medical Center, Lebanon, New Hampshire, UNITED STATES OF AMERICA.

Submission Date: 15-02-2023; Revision Date: 13-03-2023; Accepted Date: 22-03-2023.

## ABSTRACT

Detection of mosaicism in prenatal genetic screening or diagnostic tests has always been a challenge both technologically and in predicting clinical outcomes. Riddled with concerns of false positives, confined mosaicism and other technological limitations, mosaicism can pose significant challenges in leading to an accurate diagnosis. Here we present a case where unique mosaicism was detected following a case of the high-risk non-invasive prenatal screening test (NIPT). Currently, as the most sensitive prenatal screening test, NIPT has proven consistency in even identifying mosaic cases of trisomies. Choosing the appropriate confirmatory test for a high-risk NIPT becomes all the more important for accurate counselling, diagnosis and taking further reproductive decisions.

**Keywords:** NIPT, FISH, Prenatal Diagnosis, Mosaicism, Monosomy 21.

## Correspondence:

**Shiva Murarka,**  
Department of Molecular Genetics, Neuberg Supratech Reference Laboratories, Ahmedabad, Gujarat, INDIA.

Email id: shiva.murarka@ncgmglobal.com

## INTRODUCTION

Non-Invasive Prenatal Testing (NIPT) has changed the prenatal clinical testing paradigm since its introduction in 2011. The principle of NIPT relies on maternally circulating Cell-free fetal DNA (Cff-DNA). Cff-DNA is considered to be a predictor of the fetal genome, despite being contributed by the trophoblast layer of the placenta. NIPT has been proven to efficiently screen for common fetal aneuploidies compared to other prenatal screening tests with high sensitivity and specificity.<sup>[1]</sup> Apart from being a routine test in advanced maternal age or high-risk mothers, some countries have even adopted NIPT as a first line test in all pregnancies due to the ease and accuracy with which this test is carried out.<sup>[2]</sup>

The advantages of this technology are countless. However, NIPT still retains its position as a screening

test due to certain technical aspects and natural biological outcomes. Mosaic cell lines are one of these biological challenges of current NIPT technologies. Fetal and placental mosaicism continues to be major contributors to discordant NIPT results despite advances in technology. As a result, renowned reproductive medical societies recommend diagnostic testing following a high-risk NIPT result before termination or intervention of pregnancy.<sup>[1]</sup>

The current consensus on prenatal diagnostic testing following a high-risk NIPT is the use of Chromosomal Microarray (CMA) testing due to the increased diagnostic yield.<sup>[3]</sup> As a result, conventional techniques such as a Fluorescent-*in situ* Hybridization (FISH) analysis take a backseat even for internal lab confirmations on “high risk” NIPT results. In this communication, we highlight a unique case where CMA might not be a one-size-fits-all test.

## CASE PRESENTATION

A 24-year-old healthy G1P0 female was referred for a NIPT with an indication of increased risk for Trisomy 21 on the first trimester dual marker assay. The risk was 1 in 108 (age-related risk <1 in 1000).

### SCAN QR CODE TO VIEW ONLINE



www.ajbls.com

DOI: 10.5530/ajbls.2023.12.28

Ultrasound findings indicated a single live intrauterine pregnancy of 12 weeks and five days with unossified or absent nasal bone and a normal Nuchal Translucency (NT) of 1.6 mm.

NIPT performed at 13 weeks six days revealed an increased risk for Down syndrome (Fetal fraction = 7.79%; Z score of 6.72). The internally validated PPV-Positive Predictive Value was greater than 90% confidence.

Despite thorough counselling, the couple opted for termination of pregnancy based on the screening results alone. Confirmatory testing was performed on the Product of Conception (POC). The results are as follows:

CMA as the first line follow-up to high-risk NIPT - NORMAL. (AffymetrixCytoScan Optima®315K)

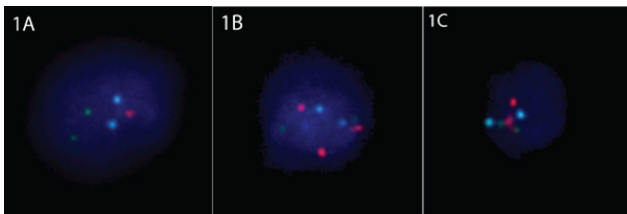
Extracted DNA was then used for second-line testing using Quantitative fluorescent PCR (QF-PCR) and Next Generation Sequencing (NGS) for aneuploidy detection - No copy number variants/Normal.

Due to high confidence in the NIPT internal data, in this case, Fluorescent-*in situ* Hybridization (FISH) analysis for chromosomes 21, 18 and 13 was performed on the remaining POC.

The FISH results revealed a cytogenetically abnormal fetus with 47% of the cells (130/277) with monosomy 21 and 44% of cells (122/277) as trisomy 21. The remaining 9% (25/277) were normal disomy cell lines (Figure 1). A Karyotype could not be performed due to sample failure. The findings reported above are based on the sample available for testing only.

## DISCUSSION

Feto-placental mosaicism contributes to 2-4% of cases with Down syndrome.<sup>[4]</sup> In this case, we report a rare combination of fetal mosaicism with Trisomy 21 (44%), Monosomy 21(47%) and Disomy 21 (9%), with almost an equal contribution of the Trisomy and Monosomy cell line identified in the POC sample



**Figure 1: FISH results of interphase cells (a) Cell with monosomy of chromosome 21 (b) Cell with trisomy of chromosome 21 (c) Cell with disomy of chromosome 21. Colour Legend: RED - chromosome 21; Green - chromosome 13; Blue - chromosome 18. [full page width].**

available to us. Individually each of these cell lines, with >10% mosaicism, could have been picked up on CMA/QF-PCR/NGS technology.<sup>[5]</sup> However, the complementary nature of the cell lines within this sample evaded the standard first-line tests following a high-risk NIPT. Retrospectively we postulate since all these tests analyse DNA at a molecular level, the abnormal cell lines were not detected due to the genomic complementarity of equally contributing cell lines. This interesting combination of mosaicism eventually was detected on a more conventional method of aneuploidy detection, that is, FISH.

Thus far, very few cases in the literature have been reported with similar mosaicism. In all the previously reported cases of a complementary monosomy/trisomy 21, the presence of a structural alteration on chromosome 21, specifically isochromosome, is observed.<sup>[4-6]</sup> Theoretically, early post-zygotic mitotic errors or meiotic mid-division during gamete production can lead to isochromosome formation. Such isochromosomes are a result of a de-novo event.<sup>[7]</sup> The formation of complementary Monosomy 21 cell lines has been postulated as a result of subsequent trisomy rescue (of the isochromosome) before the blastocyst stage. To the extent of our research, no cases of mosaic cell lines of true monosomy 21 and true trisomy 21 mosaicism have been reported with a plausible biological explanation.<sup>[8]</sup> In our case, we have not been able to prove the presence of a structural rearrangement on chromosome 21 due to culture failure of the POC tissue. It can be presumed from previous similar cases that the case presented here likely had a structural alteration on chromosome 21, leading to trisomy 21, and an early process of trisomy rescue leading to the high proportion of monosomy 21 cell lines.

The case presented here is also a validation of societal guidelines (ACOG, ACMG) supporting the rationale for confirmatory diagnostic tests following a high-risk NIPT.<sup>[1]</sup> Despite the high-risk NIPT, the unique combination of cell lines posed a challenge during the confirmatory tests. The confidence in the internally validated PPV metrics and the process of genetic counselling were major drivers in establishing an accurate diagnosis in this case. It encourages the need for further investigation to corroborate a high PPV.

As observed from clinical experience, many diagnostic labs have initiated offering one confirmatory test as a follow-up to positive NIPT results. However, there is no standardisation in the requirement to offer a confirmatory test or the type of test offered. For many labs, microarray has been the test of choice with its higher diagnostic yield and ease of efficiently analysing

the entire genome. A microarray is effective in picking up unbalanced copy number variants even at a single exon level (as low as 200Kb) and detects mosaicism as low as 10-15%, specifically in SNP-based arrays.<sup>[3]</sup> However, CMA is unable to detect balanced chromosomal defects and balanced levels of mosaicism.

## ACKNOWLEDGEMENT

We thank Dr M Shanthi Karunanithi, DGO (Sri Ragavendhra Hospital, Sendamangalam, Nammakal, Tamil Nadu 637409) for her support and coordination with the case. We thank the entire Neuberger Centre for Genomic Medicine team for their support and care of patients.

## CONFLICT OF INTEREST

The authors declare that there is no conflict of interest.

## ABBREVIATIONS

**NIPT:** Non-invasive prenatal testing; **Cff-DNA:** Cell-free fetal DNA; **PPV:** Positive Predictive Value; **MoM:** Multiples of Median; **CMA:** Chromosomal Microarray; **FISH:** Fluorescent *in situ* hybridization; **NGS:** Next Generation sequencing; **QF-PCR:** Quantitative fluorescent polymerase chain reaction; **NT:** Nuchal translucency; **T21:** Trisomy of chromosome 21; **M21:** Monosomy of chromosome 21; **POC:** Products of conception.

## SUMMARY

Our case is an endorsement of the use of FISH technology in detecting rare mosaic cases, especially in time-sensitive prenatal situations. The FISH technology can accurately identify whole chromosome aneuploidies

and low-level and complementary mosaic cell lines with higher efficiency. We propose labs consider using FISH as a first-line diagnostic test in confirmation of common aneuploidies following a high-risk NIPT. A chromosomal microarray can be considered following normal FISH results in high-risk cases for common aneuploidies. Our case represents the obligation for accurate diagnosis that laboratories and genetic counsellors have to consider when fetoplacental mosaicism is considered a possibility.

## REFERENCES

1. Brison N, Neofytou M, Dehaspe L, Bayindir B, Van Den Bogaert K, Dardour L, *et al.* Predicting fetoplacental chromosomal mosaicism during non-invasive prenatal testing. *Prenat Diagn.* 2018;38(4):258-66. doi: 10.1002/pd.5223, PMID 29388226.
2. Bedei I, Wolter A, Weber A, Signore F, Axt-Fliedner R. Chances and challenges of New Genetic Screening Technologies (NIPT) in prenatal medicine from a clinical perspective: a narrative review. *Genes.* 2021;12(4):501. doi: 10.3390/genes12040501, PMID 33805390.
3. Hao M, Li L, Zhang H, Li L, Liu R, Yu Y. The difference between karyotype analysis and chromosome microarray for mosaicism of aneuploid chromosomes in prenatal diagnosis. *J Clin Lab Anal.* 2020;34(12):e23514. doi: 10.1002/jcla.23514, PMID 32864771.
4. Krasikov N, Takaesu N, Hassold T, Knops JF, Finley WH, Scarborough P. Molecular and cytogenetic investigation of complex tissue-specific duplication and loss of chromosome 21 in a child with a monosomy 21 phenotype. *Am J Med Genet.* 1992;43(3):554-60. doi: 10.1002/ajmg.1320430310, PMID 1605248.
5. Nguyen HP, Riess A, Krüger M, Bauer P, Singer S, Schneider M, *et al.* Mosaic trisomy 21/monosomy 21 in a living female infant. *Cytogenet Genome Res.* 2009;125(1):26-32. doi: 10.1159/000218745, PMID 19617693.
6. Pooh RK, Masuda C, Matsushika R, Machida M, Nakamura T, Takeda M, *et al.* Clinical validation of fetal cfDNA Analysis Using Rolling-Circle-Replication and Imaging Technology in Osaka (CRITO Study). *Diagnostics.* 2021;11(10):1837. doi: 10.3390/diagnostics11101837.
7. Papavassiliou P, Charalsawadi C, Rafferty K, Jackson-Cook C. Mosaicism for trisomy 21: a review. *Am J Med Genet A.* 2015;167A(1):26-39. doi: 10.1002/ajmg.a.36861, PMID 25412855.
8. Burgess T, Downie L, Pertile MD, Francis D, Glass M, Nouri S, *et al.* Monosomy 21 seen in live born is unlikely to represent true monosomy 21: a case report and review of the literature. *Case Rep Genet.* 2014;2014:1-6. doi: 10.1155/2014/965401.

**Cite this article:** Rajakumar N, Sharda S, Bhatt S, Shah P, Murarka S. A Unique NIPT Discordance: FISH Comes to Rescue. *Asian J Biol Life Sci.* 2023;12(1):203-5.