

Ten years of PAM: Cases, Laboratory Protocols and Therapeutic Approaches

Giovanni De Jesus Milanez*

Department of Medical Technology, Far Eastern University, Manila, PHILIPPINES.

Submission Date: 15-09-2019; Revision Date: 11-11-2019; Accepted Date: 16-12-2019

ABSTRACT

Primary Amoebic Meningoencephalitis (PAM) is considered as one of the health challenges in the medical field due to its fatal outcome to the host. This condition is caused by infection of the protozoan *Naegleria fowleri*. Since the time of its description in 1965 by Fowler and Carter, there are only approximately 250 cases reported worldwide and almost 90% of these cases have a fatal outcome. Its rare occurrence and difficulty in diagnosing makes it a considerable public health concern. This review aims to at least provide an update on the current cases, strategies and therapeutic approaches in the treatment and management of PAM in the health care setting in the last ten years (2008-2018). Due to the rare occurrence of the condition, a total of only 45 related articles using the PubMed database were included in this review. Key words used to come up with this review included “*Naegleria*”, “*therapeutic approach*”, “Primary Amoebic Meningoencephalitis” and “cases”. Studies which include the isolation of *Naegleria spp* from environment sources as well as non-human occurrences were excluded from this review. From the investigated studies from the source database, 1 out of 12 or 8.3% of PAM cases had a positive outcome where the patient had complete recovery from the condition. Although majority of cases underwent almost the same combination therapeutic regimen which includes amphotericin B and rifampicin, it seems that the key to complete recovery from this condition is the efficiency of the diagnostic procedure given to the patient by clinicians.

Key words: Amphoteric B, Free living amoebae, *Naegleria sp.*, PAM, PCR.

Correspondence:

**Giovanni De Jesus
Milanez,**

Department of Medical
Technology, Far Eastern
University, Manila-1015,
PHILIPPINES.

Phone no: +632 9952702107

Email: gmilanez@feu.edu.ph

INTRODUCTION

Primary Amoebic Meningoencephalitis (PAM) is a fatal central nervous system condition caused by the amoeboid flagellate *Naegleria fowleri*. This amphizoic organism was first described by Fowler and Carter in 1965 involving 4 cases of severe meningitis in Australia.^[1] Since its description, occurrence of this fatal condition has been known globally.^[2] There are only approximately, 250 reported cases of PAM around the world and survival rate of infected individuals are considered low. *Naegleria sp.* can be separated from the other parasitic

free-living amoebae by its ability to exist in three morphologic forms: Cystic, trophozoite and flagellated forms. The trophozoite form is considered as the infective stage and responsible for the development of this condition in the human host. This life stage of the organism along with the other forms is present in freshwater lakes, swimming pools and recreational hot springs.

The course of infection of *Naegleria fowleri* begins when the organism gains access to the nasal epithelium through accidental inhalation of water positive with trophozoites.^[1] The trophozoite then uses the olfactory bulb as route and crawls up the olfactory nerve from which they cross the cribiform plate to reach the neuroepithelium where it induces a lytic necrotic hemorrhage of brain tissues.^[3] The parasite is able to cause tissue destruction by secreting elastase, a proteolytic enzyme believed to be attributed to the organisms virulence.^[4] The course of infection of PAM is fast and may be complete and fatal in a span of 5-7 days upon onset

SCAN QR CODE TO VIEW ONLINE



www.ajbls.com

DOI :
10.5530/ajbls.2019.8.16

of symptoms with no medical intervention.^[5] Due to the rapid onset of the disease, there is no ample time for the body to react immunologically via the humoral immune response. Moreover, the lack of distinct symptomatology of this condition poses several challenges to clinicians in providing definitive diagnosis in the early onset of infection since PAM greatly resembles bacterial and viral meningitis symptoms such as: high fever, nuchal rigidity, a positive Kernigs and Brudzinsky sign, nausea and vomiting.^[3] The history of having contact with fresh water proves to be valuable information in the early diagnosis of PAM and may be instrumental in providing an effective therapeutic regimen. Unfortunately, medical protocols would tend to oversee this piece of information especially when presented by general symptoms that most often would lead clinicians to suspect bacterial or viral meningitis instead of the protozoan form.

MATERIALS AND METHODS

This review has been conducted by compiling documented cases of PAM through PubMed search engines database from 2008 to 2018. Search keywords included “*Naegleria*”, “*therapeutic approach*”, “*Primary Amoebic Meningoencephalitis*” and “*cases*”. Due to the rare occurrence of this condition only 45 articles matched the search but only 22 are considered in this review. Also included in the study are approaches in therapeutic regimen given to patients as well as the possible laboratory methods that can be provided to patients for faster identification of the organism. Articles that involved PAM cases from non-human sources as well as answers to scientific quizzes and questions as well as isolation of *Naegleria* spp. from environmental sources were excluded from the study.

RESULTS

Epidemiology and Reported Cases of PAM (2008 – 2018)

Although *Naegleria fowleri* is considered to be widespread along with other free-living amoebae in the environment, cases concerning PAM are still considered a rare medical condition. In fact, from its first description in 1965, there are only an estimated 300 cases worldwide, 111 cases from this figure are coming from the United States.^[6] Due to its rarity in the clinical setting, familiarity of microscopist to the parasite causing PAM is considered a major pit fall in the successful early diagnosis of this condition. In the last decade, there are 12 cases

of PAM worldwide. Three (25%) of these cases came from the US^[7-9] and have occurred during the summer months. Table 1 shows PAM cases per country as well as the therapeutic regimen given to patients. Gathered data suggested that cases are spread out across age groups and that majority of people who contracted this organism had a history of swimming in infected waters. Although other forms of infection routes should be considered based on cases that does not involved contact with water. Furthermore, geographically speaking, case incidences of infection are still limited to countries that are known to have a temperate climate which reinforces the organisms’ thermophilic nature.

Microscopy

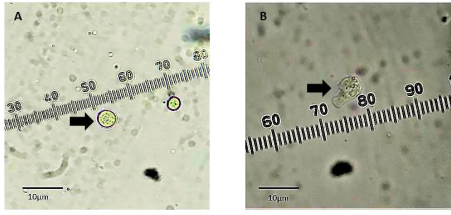
Due to the rapid onset of PAM and its fatal outcome, the early diagnosis of this condition is vital for the survival of the patient suffering from this condition. Although neurological symptoms and a history of exposure to *Naegleria fowleri*-infested freshwater may provide a vital piece of information for early diagnosis, this, however may prove inconclusive for PAM infection. The manifestation of motile trophozoite stained with Trichrome or Giemsa stain in wet mount preparations of cerebral spinal fluid may be considered as the method of choice for early diagnosis of PAM.^[4] This method, however, requires a great deal of skill on the microscopists part in accurately differentiating trophozoites from WBC’s (mostly PMNS) especially when the trophozoite count is low in CSF specimens.

Culture Methods

The use of Non nutrient agar lawned with either live or killed *Escherichia coli* and media containing low nutrient concentrations proved to be an effective way to grow and isolate FLAs which include *Naegleria* sp. Although other choice of bacteria as food source is not exclusive to the organism, it is however important to consider to select non mucoid strains of bacteria since the presence of mucoid capsule inhibits phagocytosis of growing trophozoites and eventually affects further proliferation of FLAs in the culture medium.

Analysis of Cerebrospinal Fluid

Although the absence of active trophozoite may be unlikely, correlation of CSF chemistry results such as an elevated protein level (100-1000 mg/dl), an elevated CSF pressure (up to 600 mm H₂O), an elevated RBC and WBC counts (up to 26,000 mm³/ml) and low CSF glucose levels (< 10 mg/dl) may prove to be helpful in suspecting possible infections.^[4]



Micrographs of isolated *Naegleria* sp. (A) cyst and (B) trophozoite. Photos courtesy of G. Milanez, Far Eastern University Manila.

Molecular Methods

The development of molecular testing through the use of Polymerase Chain Reaction (PCR) has further improved the efficiency of specific identification of *Naegleria fowleri* in clinical samples. Researchers were able to exploit gene markers specific to this organism, making identification more accurate and precise. Among the gene markers used include the internal transcribe spacer region and the 18S rRNA, which are considered highly variable regions.^[10] The development of multiplex PCR offers differential diagnosis in clinical samples that enables clinicians to distinguish PAM infections from other CNS infections which are caused by other parasitic organism other than *Naegleria fowleri* that may require a different therapeutic regimen.^[11] Because it involves multiple primers used which are specific to each different species, multiplex PCR does not only provide an accurate and precise identification but most importantly it has a faster turnaround time when it comes to delivery of results compared with conventional PCR methods.

Other Methods of Identification

The use of radiologic techniques such as Computed Tomography (CT) and Magnetic Resonance Imaging (MRI) may provide valuable information on the extent of the damage done by thriving trophozoite in the brain. In fact, in a study conducted in the United States, 33% of PAM patients who have undergone CT and MRI scanning provided the same abnormal descriptions such as cerebral edema with effacement of the cortical sulci and basilar cisterns, leptomeningeal enhancement, decrease in the size of ventricles, areas of hemorrhage or necrosis and herniation.^[7] Although this is the case, CT and MRI cannot establish the presence of the organism in the brain and clinicians may still need to rely on microscopic examination of CSF. Electroencephalogram may also provide decreased electric activity on all patients, but this should still be needed to be correlated with other clinical results since it resembles other forms of meningitis such as viral and bacterial.

Development of Microscopic Methods

The development of microscopic methods such as the use of Scanning Electron Microscopy (SEM) and Transmission Electron Microscopy (TEM) in identifying FLAs has been instrumental in understanding the different mechanisms involve in the direct effects of several experimental drugs to different forms of the organism. Several studies have used the efficiency of SEM to described structural damage of certain microorganisms to the cellular integrity of the cyst wall of test FLAs.^[12] Furthermore, the use of high level magnification microscopy such as SEM and TEM has helped researchers through the years to differentiate structural differences from one species to another in a microscopic level.^[13] These developments have further helped both researchers and clinicians alike in developing therapeutic regimens to patients suffering from amoebic encephalitis by formulating effective anti-amoebicidal drug targeting vulnerable structures of the organism.^[14]

Successful therapeutic approaches against PAM

Due to the severity and fatal outcome of the disease process of PAM, several experimental drugs have been tested *in vitro* to effectively kill the protozoan inside the host it infects. Also, early diagnosis and aggressive treatment appears to be the common key in the treatment regimen provided to patients who contracted this organism. It appears that the combination therapy of Amphotericin B, Rifampicin and antifungal drugs are the most common drug therapy given to patients suffering from PAM. Although administration of these drugs to patients will not assure survival, they are still considered the primary therapeutic regimen so far in the treatment of PAM in the clinical setting.^[15]

For this reason, several experimental treatment drugs have been used and have been added to the conventional combination drug therapy being administered to patients with PAM. One of the promising drugs includes miltefosine.^[16] In three cases of patients suffering from PAM, an anti-leishmania drug known as miltefosine was administered, two of the three patients managed to survive, with one patient undergoing full recovery from the disease.^[17] Although the exact effect of the drug to *Naegleria* sp. has not been further studied, miltefosine in combination with other therapeutic drugs such as Amphotericin B, Rifampicin, fluconazole.^[18] and chlorpromazine has been proven effective both *in vivo* mice models and *in vitro* studies.^[19]

In a another study, the antirheumatic drug auranofin has been tested with axenic cultures of pathogenic strains of *Naegleria fowleri* and have been founded to have amoebicidal effect on the protozoan resulting to the decreased

Table 1: Documented PAM cases, profile of patients, therapeutic regimen given and outcome for the last 10 years (2008-2018).

Country	Age of Patient	Gender	Year	Transmission to Host	Method of Diagnosis	Therapeutic Regimen	Outcome
India	6 month old	M	2010	Well water used to bathe child - negative when sampled and cultured	Blood Chemistry, Hematology Testing, HIV testing, CSF wet mount,	Diazepam - Seizures, Amphotericin B, Chloramphenicol, Metronidazole	Dead
India	20 yr old	M	2009	No history of swimming	CT scan, Blood count, CSF test	Amphotericin B and Rifampicin	Dead after 16 days
Iran	5 month old	M	2012	No history of swimming	CBC, CT, CSF wet mount (initial test negative for amoebae)	Vancomycin and Ceftriaxone (bacterial meningitis), Amphotericin B and Rifampicin	Alive
Costa Rica	11 year old	M	2014	Swimming in hot spring and pond	CSF wet mount	none	Dead after 72 hr
Venezuela	33 year old	M	2008	Swimming in fresh water bathe hole	CSF wet mount	None	Dead after 72 hr
Pakistan	24 year old	M	2009	Swimming	CT scan, CSF wet mount 1(neg), CSF wet mount 2	ceftriaxone and acyclovir - initial, not vancomycin and meropenem, Amphotericin B	Dead in 6 days
Pakistan	30 year old	M	2009	Swimming	CT scan, CSF wet mount 1(neg), CSF wet mount 2	ceftriaxone and acyclovir - initial, not vancomycin and meropenem, Amphotericin B	Dead in 8 days
Taiwan	75 year old	M	2013	swimming in hot springs	CBC, Blood Chemistry, HIV test, MRI, CT scan, CSF wet mounts	Amphotericin B	Dead after 21 days
Zambia	24 year old	M	2017	Swimming in River	Test for Malaria, CSF mounts (negative twice, third time on 8 day positive), CT normal	Ceftriaxone, Amphotericin B	Dead on 8 th day
United States	7 years old	F	2010	Swimming	CSF test, CT scan	Vancomycin and Ceftriaxone (bacterial meningitis)	Dead
	21 years old	F	2015	Swimming pool	CSF test (negative for trophozoites)	Vancomycin and Ceftriaxone (bacterial meningitis)	Dead after 48 hr
	4 year old	M	2013	Swimming	CT scan, CSF test	Vancomycin and Ceftriaxone (bacterial meningitis)	Dead after 4 days

amoeba count in the cultures taking into consideration the effects of auranofin to the integrity of the protozoan membrane and decreases metabolic activity of the organism.^[20]

Corifungin is another drug that has been proven to be more effective than Amphotericin B when it was tested in parallel with the latter drug both *in vitro* and in mice models. The effects of corifungin is mainly on disruption of cytoplasmic and plasma membranes of

the organism leading to complete lysis of the amoebae. More so, confurigin has been approved by the FDA as an orphan drug for the treatment of PAM in the United States.^[21]

DISCUSSION

Primary Amoebic Meningoencephalitis is considered a global concern due to the fatal outcome it has to

humans who get infected by the causative protozoan *Naegleri* spp. It has a global occurrence and considering that there are no concrete therapeutic regimen given to patients who fall victim to this condition makes it a public health concern. The difficulty to diagnose this condition may be due to lack of solid symptomatology which has led to several wrong treatment regimens given to patients which eventually lead to death of the host. The fast progression of the condition in the host has been a challenge not only to clinicians but more so to researchers who have tried to discover with either a faster and efficient diagnostic procedure or an effective treatment regimen to patients. Although PAM has a very low rate of incidence globally, it may have the highest rate in mortality compared with encephalitis of bacterial and viral in origin. For this reason alone that it should be considered as a priority in terms of discovering an effective treatment protocol.

In terms of diagnostic protocol, definitive microscopic identification of the parasite in the CSF seem to be the most reliable to make a definite diagnosis. Unfortunately, most of the time this microscopic examination is done only after eliminating the possibility of bacterial or viral meningitis thus leaving PAM untreated for some time. The use of CT scans and the like may not be so useful as well in providing diagnosis for people who contracted the parasite. Culture methods may take too long to provide results which may be too late for the patient.

The discovery of therapeutic drugs may hold the key in solving the problem posed by PAM, however, host responses to certain drugs are different from another. One drug may prove to be effective to one patient but may prove ineffective to another. The response of the host to the aggressive drug treatment to PAM has been probably one of the greatest concerns to researchers and clinicians since these drugs have the same amoebicidal effect to the parasite and yet the outcome becomes different. Considering that all cases presented in this review has been given the same aggressive therapeutic regimen but the turnout of survival is low (1 out of 12 cases). There is, however, a link between the survival of the patient and the time the aggressive drug treatment is applied. This means that the early the clinicians can provide a definitive diagnosis for PAM, the sooner the drug administration can be done to the patient.

In short, clinicians may need to consider encephalitis caused by *Naegleri* sp in their routine medical history checks when faced with patients showing the same symptoms.

CONCLUSION

From the time of the discovery of *Naegleria fowleri*, researchers and clinicians have tried to come up with efficient methods in its faster diagnosis and effective therapeutic regimen. Although some therapeutic drugs are considered effective to some cases, this may not be the case for some as presented in this review. The challenge of formulating an effective therapeutic regimen and control for PAM is still a work in progress and researchers may still need to explore all possible niches to come up with one. The most effective however is the isolation of the organism from the source and share this information to the public so that measures from the health government may be established in areas where *Naegleria* sp. is present. Until the time that a vaccine or an effective drug is developed for PAM, the best way to keep us from contracting PAM is public health awareness.

ACKNOWLEDGEMENT

The author would like to thank the Department of Medical Technology, Far Eastern University for providing technical assistance in the completion of this review.

CONFLICT OF INTEREST

Author declare no conflict of interest.

REFERENCES

1. Fowler M, Carter RF. Acute Pyogenic Meningitis Probably Due to *Acanthamoeba* sp., Preliminary Report. Br Med J. 1965;2(5464):740-2.
2. DeJonckheere JF. A Century of Research on the Amoeboflagellate Genus *Naegleria*. A Century of Research on the Amoeboflagellate Genus *Naegleria*. 2014;309-42.
3. Król-Turmińska K, Olender A. Human infections caused by free-living amoebae. Ann Agric Environ Med. 2017;24(2):254-60.
4. Ferrante A, Bates EJ. Elastase in the pathogenic free-living amoebae *Naegleria* and *Acanthamoeba* spp. Infect Immun. 1988;56(12):3320-1.
5. Visvesvara GS, Moura H, Schuster FL. Pathogenic and opportunistic free-living amoebae: *Acanthamoeba* spp., *Balamuthia mandrillaris*, *Naegleria fowleri* and *Sappinia diploidea*. FEMS Immunol Med Microbiol. 2007;50(1):1-26.
6. Yoder JS, Eddy BA, Visvesvara GS, Capewell L, Beach MJ. The epidemiology of primary amoebic meningoencephalitis in the USA, 1962-2008. Epidemiol Infect. 2010;138(7):968-75.
7. Kemble SK, Lynfield R, DeVries AS, Drehner DM, Pomputius WF, Beach MJ, et al. Fatal *Naegleria fowleri* infection acquired in minnesota: Possible expanded range of a deadly thermophilic organism. Clin Infect Dis. 2012;54(6):805-9.
8. Fletcher A. Primary Amebic Meningoencephalitis Associated with Exposure to Swimming Pool Water Supplied by an Overland Pipe—Inyo County, California, 2015. Art Bull. 2012;94(3):350-1. Available from: <http://search.ebscohost.com/login.aspx?direct=true%7B&%7Ddb=a9h%7B&%7DAN=82192943%7B&%7Dsite=ehost-live>

9. Cope J, Rattard R, Hill V, Sokol T, Causey J, Yoder J, *et al.* The First Association of a Primary Amebic Meningoencephalitis Death with Culturable *Naegleria fowleri* in Tap Water from a U.S. Treated Public Drinking Water System. 2017;60(8):e36-42.
10. Capewell LG, Harris AM, Yoder JS, Cope JR, Eddy BA, Roy SL, *et al.* Diagnosis, Clinical Course and Treatment of Primary Amoebic Meningoencephalitis in the United States, 1937–2013. Journal of the Pediatric Infectious Diseases Society. 2014;4(4):1-8.
11. Sheehan K, Fagg J, Ferris M, Henson J. PCR Detection and Analysis of the Free-Living Amoeba *Naegleria* in Hot Springs in Yellowstone and Grand Teton National Parks. Appl Environ Microbiol. 2003;69(10):5914-8.
12. Sampaotong T, Lek-Uthai U, Roongruangchai J, Roongruangchai K. Viability and morphological changes of *Acanthamoeba* spp. cysts after treatment with Effective Microorganisms (EM). J Parasit Dis. Springer India. 2016;40(2):369-73. Available from: <http://dx.doi.org/10.1007/s12639-014-0511-x>
13. Lastovica AJ. Scanning electron microscopy of pathogenic and non-pathogenic *Naegleria* cysts. Int J Parasitol. 1974;4(2):139-42.
14. Mahboob T, Azlan AM, Tan TC, Samudi C, Sekaran SD, Nissapatorn V, *et al.* Anti-encystment and amoebicidal activity of *Lonicera japonica* Thunb. and its major constituent chlorogenic acid *in vitro*. Asian Pac J Trop Med. Elsevier B.V. 2016;9(9):866-71.
15. Yadav D, Aneja S, Dutta R, Maheshwari A, Seth A. Youngest survivor of *Naegleria meningitis*. Indian J Pediatr. 2013;80(3):253-4.
16. Heggie TW, Küpper T. Surviving *Naegleria fowleri* infections: A successful case report and novel therapeutic approach. Travel Med Infect Dis: Elsevier Ltd. 2017;16:49-51. Available from: <http://dx.doi.org/10.1016/j.tmaid.2016.12.005>
17. Cope JR, Conrad DA, Cohen N, Cotilla M, Dasilva A, Jackson J, *et al.* Use of the Novel Therapeutic Agent Miltefosine for the Treatment of Primary Amebic Meningoencephalitis: Report of 1 Fatal and 1 Surviving Case. Clin Infect Dis. 2015;62(6):774-6.
18. Chanpimol S, Seamon B, Hernandez H, Harris-love M, Blackman MR. HHS Public Access. 2017;135(3):1-9.
19. Kim JH, Jung SY, Lee YJ, Song KJ, Kwon D, Kim K, *et al.* Effect of therapeutic chemical agents *in vitro* and on experimental meningoencephalitis due to *Naegleria fowleri*. Antimicrob Agents Chemother. 2008;52(11):4010-6.
20. Peroutka-Bigus N, Bellaire BH. Anti-Parasitic Activity of Auranofin Against Pathogenic *Naegleria fowleri*. J Eukaryot Microbiol. 2018;1-2. Available from: <http://doi.wiley.com/10.1111/jeu.12706>
21. Debnath A, Tunac JB, Galindo-Gómez S, Silva-Olivares A, Shibayama M, McKerrow JH. Corifungin, a new drug lead against *Naegleria*, identified from a high-throughput screen. Antimicrob Agents Chemother. 2012;56(11):5450-7.

Cite this article: Milanez GDJ. Ten years of PAM: Cases, Laboratory Protocols and Therapeutic Approaches. Asian J Biol Life Sci. 2019;8(3):97-102.